



IN THIS ISSUE

Page 1

Clinical Case Review: Bi-Lateral Flapless Sinus Lifts
Dr. Arturo R. Garcia

Page 2

Letters-to-the Editor Tidbits

Page 4

Case Study: Maxillary Torus No Match For Implant Retained Denture
Dr. Frank Rugani
Dr. Timothy Kosinski

Page 12

CE Programs

To Subscribe to

Implant News & Views

call

1-888-385-1535

1-516-593-3806
outside the US

or email us at

dentpub@optonline.net

or visit our website at

implantnewsandviews.com

Check Out our Comprehensive Implant CE Course Listings [over 400 courses]

at our website

implantnewsandviews.com

Case Study: Maxillary Torus No Match For Implant Retained Denture

Frank C. Rugani, DDS and Timothy Kosinski, DDS, MAGD

The patient was a healthy 82 year-old female. Following extensive periodontal surgery, six maxillary and teeth #'s 18, 20-28 and 30 were maintained for well over 25 years. A maxillary swing lock appliance replaced teeth #'s 2,3,4,5,12,13,14 and 15. A conventional mandibular partial denture replaced teeth #'s 19, 29 and 31.

A large maxillary torus prevented the possibility of fabricating a conventional maxillary complete denture after it was determined that teeth #'s 6-11 were no longer adequate abutments. Removable of the maxillary torus could be a complicated procedure for this patient. The patient was insistent that she be restored immediately with some appliance following extraction of the periodontally involved #6-11.

Surgical Placement

It was decided that dental implants would be surgically placed in the maxillary arch. Because of the large torus, a horseshoe shaped transitional denture was fabricated for the patient during the integration process. However without a retentive mechanism this denture would have no viable stability and the use of denture adhesive during initial healing is contraindicated. Tapered 4.7 mm X 13 mm Screw-Vent implants were conventionally placed in the #4, 8,9, and 13 areas and 4.7mm X 16mm implants placed in the #6 and 11 areas.

Second phase healing collars were threaded into the implants and

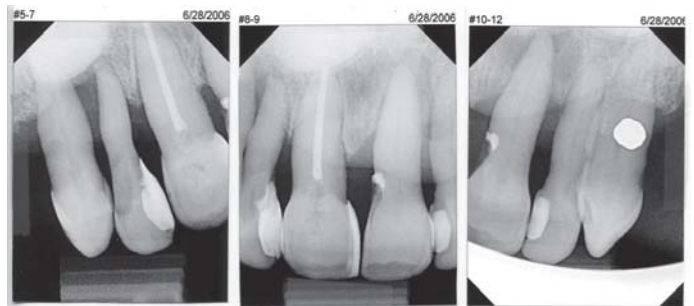
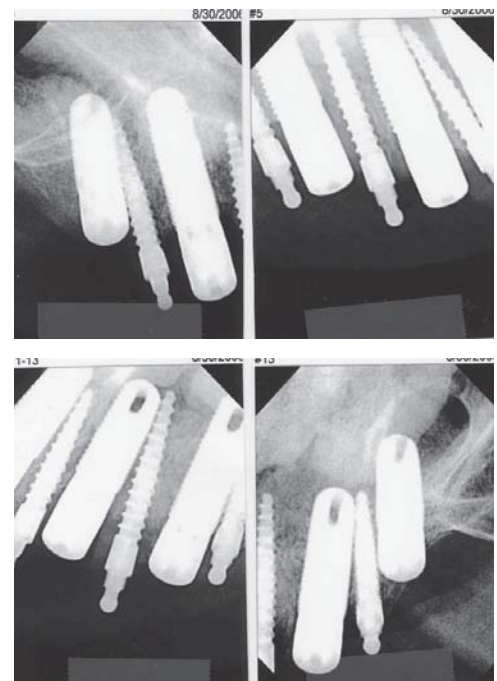


Fig. 1 - Pre-op radiographs of non treatable teeth #'s 6-11.



Figs. 2- 2a - Radiographs of implants in position.

the tissue allowed to heal around them. To improve initial stability and retention of the interim denture, IMTEC 15mm small diameter implants were immediately placed in the #5,7, 10 and 12 areas and a 13mm IMTEC implant placed between implants #8 and 9. The surgical procedure was completed without complication and the patient tolerated the placement of the implants well.

Provisionalization

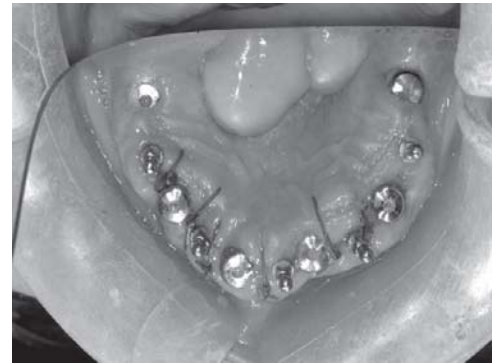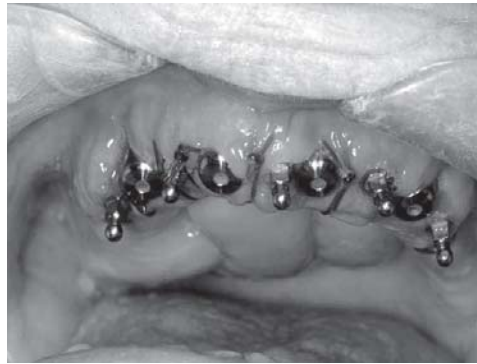Upon placement of the dental implants and exposed small diameter implants, the transitional, horseshoe shaped denture was delivered using a soft liner. The small diameter implants worked well in stabilizing the denture, adding needed retention during the entire healing process.

A conventional mandibular partial denture was fabricated replacing teeth #'s 18,19,23,24,25, 26,29,30 and 31. After approximately two months, three of the anterior small diameter implants were removed and O rings placed in the posterior ones. The transitional denture was relined again.

Hadar Bar

After three months of integration, conventional implant impression techniques were used to fabricate a master cast for a new implant retained bar and Hader clip maxillary prosthesis. The remaining two small diameter implants were removed prior to final seating of screw retained bars. Six Hader clips were used to create adequate retention.

The patient was thrilled with the final esthetic and retentive prosthesis. A quality of life was restored after a relatively short period of time. Implant dentistry



Figs 3-4 - Facial and occlusal view of 6 Screw Vent dental implants and 5 small diameter implants used to initially retain a transitional horseshoe shaped denture.

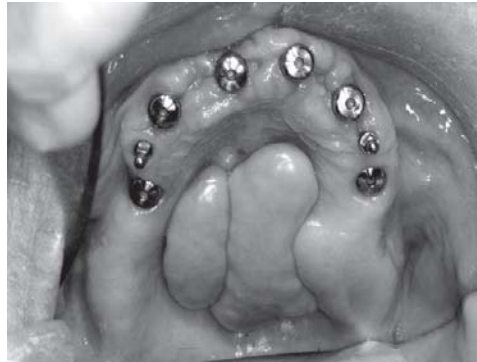

Fig. 5 - Two month post op healing.

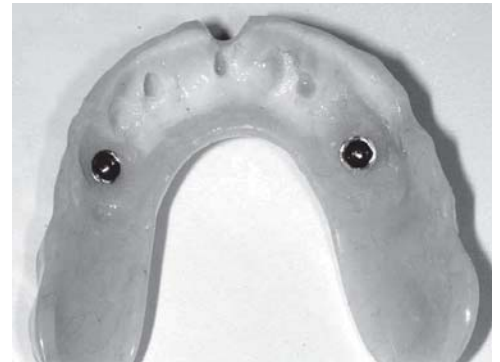
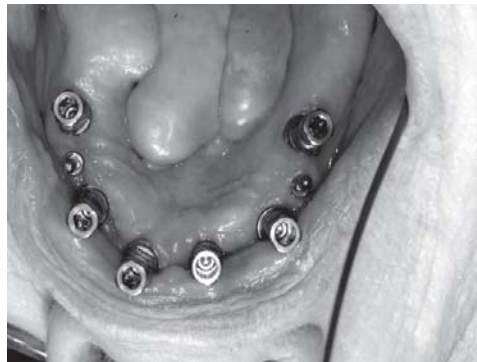
Fig. 6 -Transitional, horseshoe shaped denture with retentive O-rings into small diameter implants and a soft liner.



Figs 7- 8 - Conventional implant impression techniques were used to create a master cast.

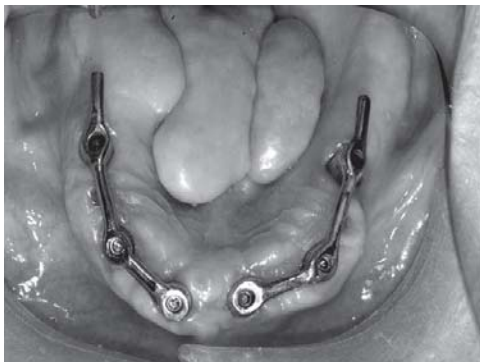
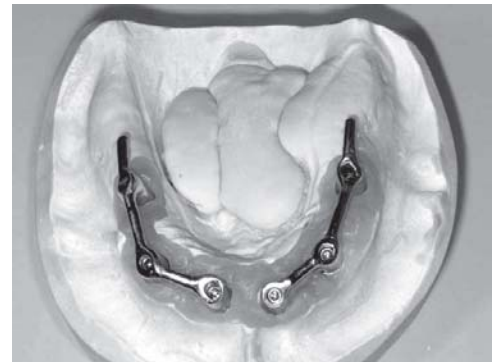
Fig. 9 -Implant retained Hader bars in position.

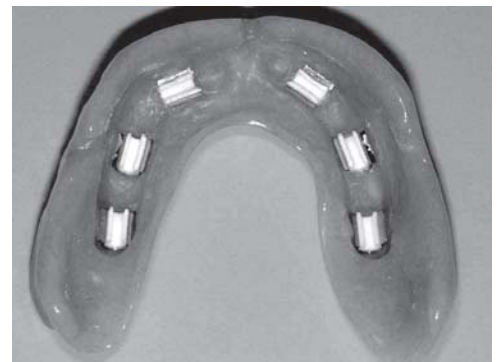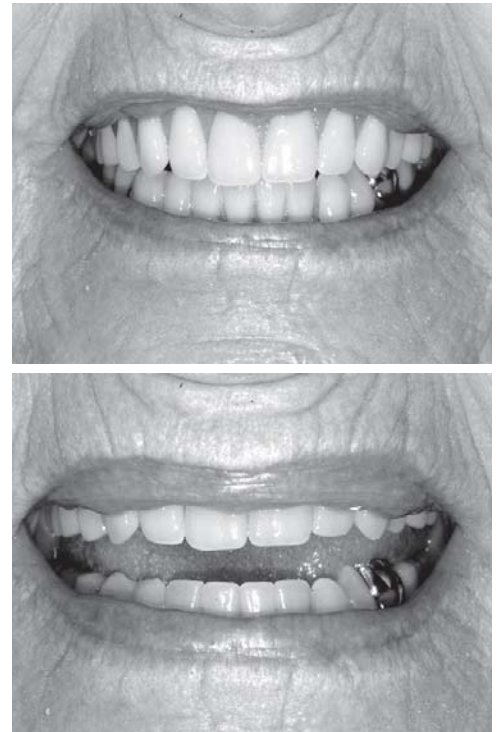


Fig. 10 - Horseshoe shaped denture with retentive Hader clips.

again proved to be an outstanding treatment option in an unusual situation.

Frank C. Rugani, DDS is an associate in a general and implant practice in Houghton, MI. He is a member of the AGD, a Fellow of the ICOI and a member of the Academy of Osseointegration.

Timothy Kosinski, DDS, MAGD maintains a private practice in Bingham Farms, MI with an emphasis on cosmetic and implant dentistry. He is an Adjunct Assistant Professor at the University of Detroit Mercy School of Dentistry, serves on the editorial review Board of *Reality*, and is a Diplomat of the American Board of Oral Implantology/Implant Dentistry, the International Congress of Oral Implantologists and the American Society of Osseointegration. He is a Fellow of the American Academy of Implant Dentistry and received his Mastership in the AGD. He can be reached at allquestions@smilecreator.net or 248-646-8651.



Figs 11-12 - Final prosthesis in place.

Reprint Courtesy of [Implant News & Views](#)
888-385-1535
www.implantnewsandviews.com