

Socket Preservation Technique Critical for Implant Bone Preparation

Timothy Kosinski, DDS, MAGD

Implant dentistry is an innovative and comprehensive mode of treatment for replacing missing teeth. Tooth loss is the result of many factors including gross decay, trauma, periodontal disease and/or endodontic complications. Alveolar bone has a tendency to collapse following extraction. This may create future difficulties in placing a dental implant. Without socket preservation techniques, the resorption of the alveolar bone is 40-60% within the first two or three years¹.

This natural resorption can be reduced by placing an augmentation material into the socket following curettage of any granulation tissue and covering the site with a resorbable or non resorbable barrier matrix. Keeping bone height intact may be a critical aspect to the surgical and prosthetic success of any implant. Allowing bone to shrink over time can make implantation difficult or impossible without expensive bone regeneration procedures. Therefore, it is to the benefit of the treating dentist and the patient to attempt to maintain bone height and width following extraction.

Stress Sites

All skeletal bone demonstrates volume stability over time except dental alveolar bone. This is because the dental alveolus is very labile in the absence of loading. Wolff's Law states that remodeling of bone occurs in response to physical stress. Bone deposition occurs at stress sites and bone is resorbed where there is little or no stress. During the removal of teeth several things occur. There is loss of crucial support plates, loss of vascularity of the alveolar processes, ultimate bone resorption, crestal bone loss, site collapse of the buccal/lingual plates and potential bone loss on adjacent teeth.^{2,3} The obvious advantages of socket preservation is prevention of bone loss of the extraction site, restoration of the defect back to its original shape, prevention of soft tissue collapse in the extraction site and the graft material sequesters intergratable bone so we can plan for a better and more predictable restorative future.

GTR

Guided tissue regeneration is a procedure that enables bone and tissue to grow into a desired area. The mechanisms of bone regeneration consists of several processes. Osteogenesis is the ability to create viable bone cell development. Osteoinduction is the ability to stimulate those cells capable of formulating bone cells like bone morphogenetic proteins and platelet derived growth factors. This is a chemical process. Osteoconduction is a structure that is used to support or scaffold bone development. This is a physical process. Platelet derived growth factors stimulate cell proliferation and healing cascades in bone and other cell types. These proteins are produced from mesenchymal cells or released by platelets during clotting.⁴

Graft Materials

There are many materials on the market today that are used during socket preservation procedures. The general categories of bone augmentation materials are autogenous, allografts, xenografts and alloplastic materials. Autogenous graft materials are certainly the "golden" standard. It is harvested from the patient's own body but requires a second surgical site for harvesting of material. Often these sites are the symphysis or ramus. Therefore the material is limited in supply and there is added time for processing and healing of two sites, potential surgical morbidity and an increased chair side procedure time.

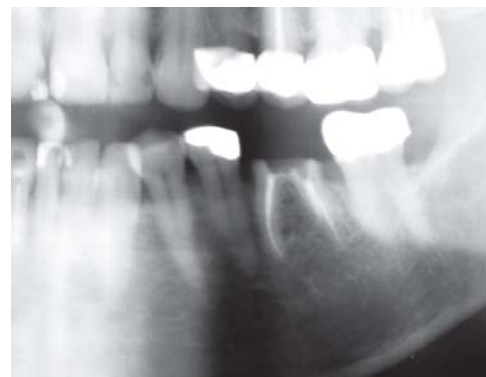

Fig. 1 - Preoperative radiograph illustrating non restorable mandibular left mandibular first molar.

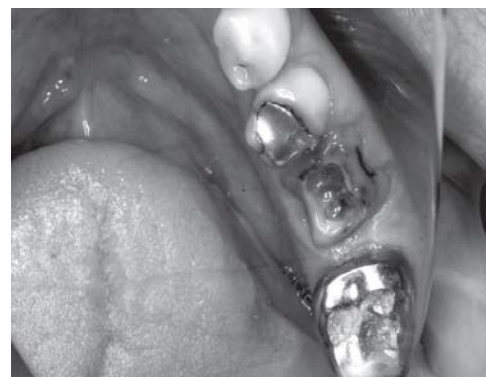

Fig. 2 - Occlusal view of fractured mandibular first molar.

Morphogenetic Proteins

Another source of augmentation material is bone morphogenetic proteins (BMP) which consist of proteins that are found in everyone's body and a natural carrier. The protein is an engineered, and not naturally occurring, recombinant human bone morphogenetic protein². The carrier is made from material found in tendons. It releases the protein over time where it is placed and provides a scaffold for new bone to grow into it and is absorbed and replaced by bone. It is a fairly expensive material to purchase.

Allografts are graft materials made from the same species but have minimal BMP activity. Mineralized pieces may not resorb and there are potential procurement and disease transmission issues.

Xenografts are primarily bovine which closely resemble human cells. Mineralized products fail to resorb and may remain radiopaque for years so you can not follow integration radiographically. There may also be disease transmission issues.

Alloplastic materials are synthetic Beta Tricalcium Phosphate. There is no risk of disease transmission, particles have a scaffolding shape for bone deposition, they release calcium on resorption, and resorption time and new bone deposition can be monitored radiographically. The material is also cost effective.

Osteoconductive

Cerasorb (Reimser, Inc. Research Triangle Park, NC) is a Beta Tricalcium Phosphate product that has eleven years of clinical data behind it. It is an osteoconductive material with excellent porosity, predictable resorption, high phase purity, long term stability and maximum compatibility. The large primary particles prevent phagocytosis by macrophages and the high solubility of the material is adjusted to the natural formation of bone. The material, when initially placed, is radiopaque. As it scaffolds bone formation the material becomes more radiolucent and bone like. The Ceresorb granules are ingrown by bone cells and blood vessels and the material degrades with simultaneous bone replacement. There is, therefore, regeneration with vital new bone.

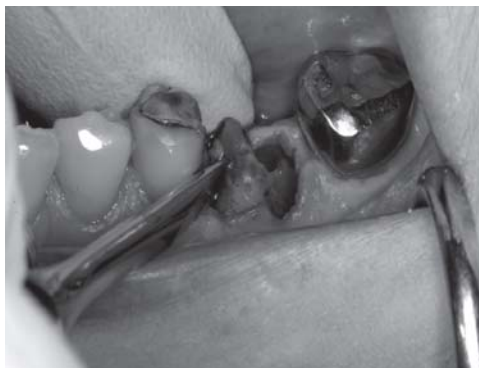

Fig. 3 - Elevator extraction of mesial and distal root.

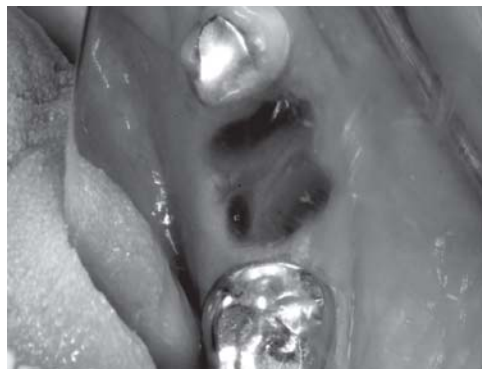

Fig. 4 - Mesial and distal socket following extraction of roots.

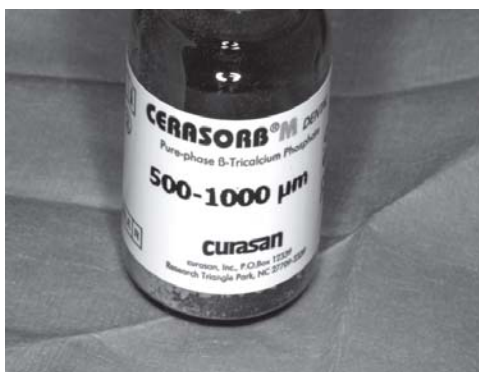


Fig. 5 -Cerasorb material 500-1000 micrometer size particles.

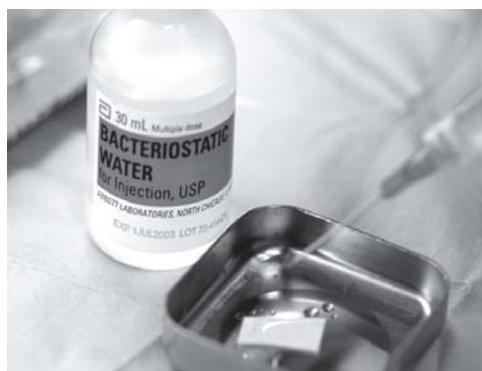

Fig. 6 - Epi Guide material being soaked with bacteriostatic sterile water.

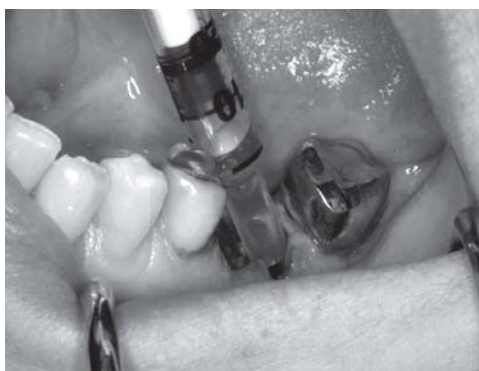

Fig. 7 - Syringing of blood from the socket site.

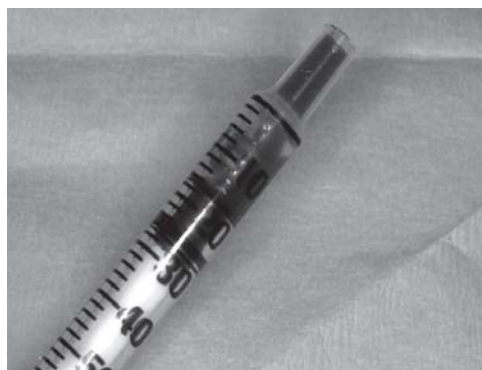

Fig. 8 - Adequate amount of blood harvested to wet the Tricalcium Phosphate particles.

Socket Preservation Technique Critical for Implant Bone Preparation

continued from p. 9

Membranes

Membranes are a critical part of bone augmentation procedures. New bone formation is enhanced by the additional use of a membrane under a periosteal lined mucoperiosteal flap. Ideal materials today can be bioresorbable, are exclusive of unwanted soft tissue epithelium, they support and protect clot formation, are space creating and protect the periodontal support tissues. They localize growth factors for bone cell production. Epi Guide membrane (Reimser Inc. Research Triangle Park, NC) has up to 20 weeks of functionality, provides self supporting structural integrity and has excellent fluid blood uptake into the matrix for clot formation and support. It is a D, D-L, L polylactic acid polymer that has a long history of safe medical use.

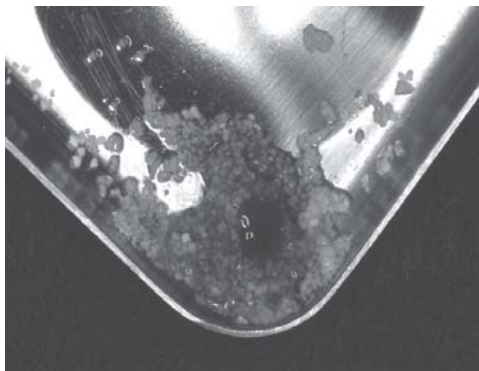

Fig. 9 -Mixing the Curesan particles with the patient's own blood.

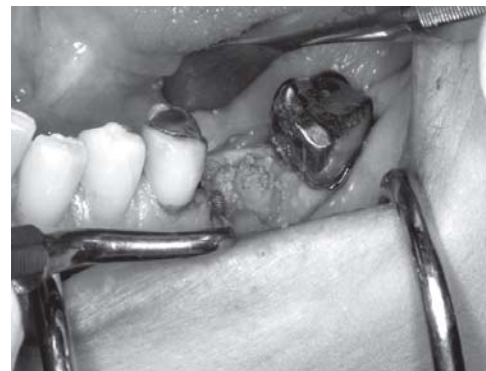

Fig. 10 -Particles packed into the socket site.

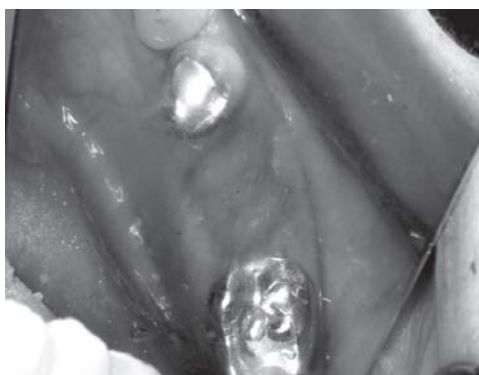

Fig. 11 - Suturing over the Epi Guide barrier.

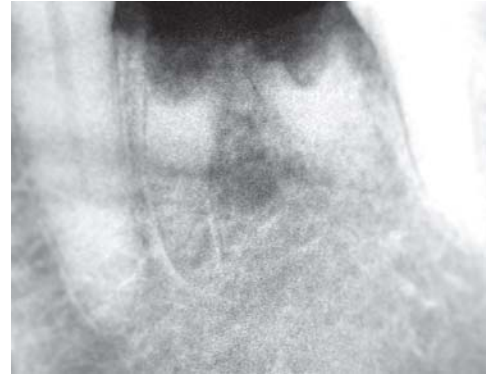

Fig. 12 -Initial radiograph illustrating radiopaque particles immediately after placement.

The use of Beta Tricalcium Phosphate materials with a biodegradable membrane barrier provides for a one step surgery, no potential for disease transmission, long term barrier function, no exposure issues and superior healing characteristics. The ability to evaluate the healing site radiographically is unique and a positive benefit. Following augmentation with Cerasorb material and covering with the appropriate membrane like Epi Guide, the bone loss of an extraction site is less than 10%.¹

Our patient presented with a non restorable mandibular left first molar which required extraction [Figs. 1-2]. No significant medical findings or contraindications were found. After discussing the prosthetic options of a conventional fixed bridge or a single dental implant, the patient elected to place an implant to provide for easier hygiene and less stresses on the adjacent abutment teeth. Dental implants have become a reasonable treatment option for a missing tooth. It was explained to the patient that when a tooth is removed the remaining alveolar ridge and socket will shrink both vertically and buccally.

Technique

Augmentation of the alveolar ridge is a good idea with either treatment option to improve esthetics and function. **Fig. 3** illustrates the non traumatic removal of the mesial and distal roots following sectioning. Care was taken not to damage the buccal or lingual plates [Fig. 4]. The patient had some concern with potential disease transmission and although mineralized/demineralized augmentation material is an option, having a synthetic material such as Curesan B Tricalcium Phosphate is crucial. The benefits and risks of each material available for use were explained to the patient. The 500-1000 micron particles of the Curesan augmentation product were chosen because they are easy to pack and control in a large socket site [Fig. 5].

While preparing the allograft material, the resorbable membrane, Epi Guide, is softened with bacteriostatic sterile water. This allows the material to be molded and managed quite easily without making a

significant flap in the extraction area [Fig. 6]. Prior to application of the Cerasorb, the material should be mixed with the patient's own blood [Figs. 7-8]. The blood obtained from the patient supplies bone forming cells like osteoblasts precursor cells, mesenchymal stem cells and thrombocytes. The latter are activated by collagen structures from surrounding tissue and by the calcium ions of Cerasorb. Gel formation is stimulated and the manageability of the mixture improves significantly [Fig. 9].

The recommended mixture ratio is one part blood to two parts Cerasorb. It is important that the wound is cleaned carefully from granulation tissue, fibrin and other residues. The bone needs to be cleaned of any soft tissue. Avoid using sodium chloride or antibiotic solutions to saturate the allograft. Cerasorb acts as a sponge. It absorbs the solution that is offered first. If it is mixed with a solution of sodium chloride or antibiotics the micropores can be saturated with it. The blood from the defect containing monocytes and thrombocytes will only invade intergranular cavities and angiogenesis, which is important for the supply of nutrition and oxygen to the new cells, will be impaired.

Healing

Regeneration of the patient's own local bone will, therefore, take place more slowly. Fig. 10 illustrates the Cerasorb granules being placed cleanly into the socket sites. Epi Guide membrane is contoured into the site and packed into the facial and lingual tissue folds and a cross linked suture placed to hold the material [Fig. 11]. Fig. 12 shows the initial periapical radiograph of the radiopaque material in place. It is easy to see. Following three months of healing, bone is forming and the radiopaque material is much more bone like radiographically, allowing us to have an objective method of determining healing in preparation for a single dental implant [Fig. 13]. The tissue over the extraction site heals well [Fig. 14]. We are now prepared to predictably place a single dental implant in a previously large extraction site.

References

1. Hille, R. Alveolar Ridge Preservation-Preserving and Building Up the bone Structure After Extraction. *Implantologie Journal*. 1, 2005. 12-18.
2. Szabo, Gyorgy et. Al. A Prospective Multicenter randomized Clinical Trial of Autogenous Bone Versus B Tricalcium Phosphate Graft Alone for Bilateral Sinus Elevation: Histologic and Histomorphometric Evaluation. *International J of Oral & Maxillofacial Implants*. 20 (1). 2005. 371-372.
3. Knabe, C. Effect of B Tricalcium Phosphate Particles with Varying porosity on Osteogenesis After Sinus Floor Augmentation in Humans. *ScienceDirect*. 29. 2008. 2249-2258.
4. Zerbo, I. et. al. Histomorphometry of Human Sinus Floor Augmentation Using a Porous B Tricalcium Phosphate: A Prospective Study. *Clinical Oral Impl. Res*. 15. 2004. 724-732.

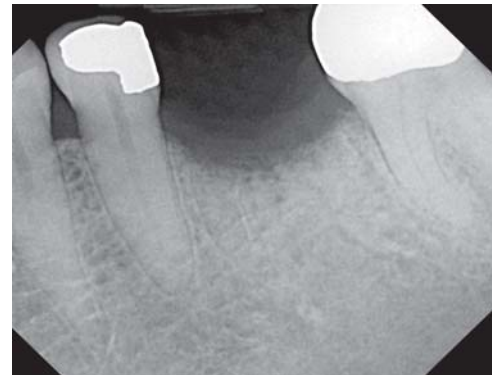


Fig. 13 - Site appears more radiolucent or bone like following three months of healing.

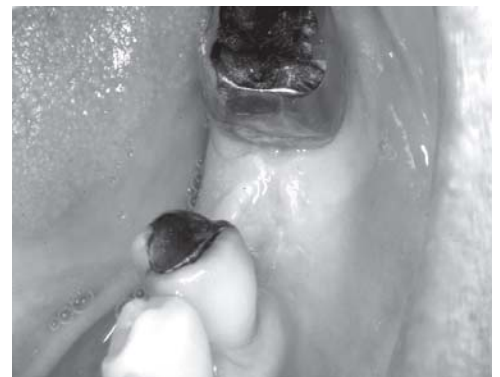

Fig. 14 - The ridge healed after 3 months.

Timothy Kosinski, DDS, MAGD maintains a private practice in Bingham Farms, MI with an emphasis on cosmetic and implant dentistry. He is an Adjunct Assistant Professor at the University of Detroit Mercy School of Dentistry, serves on the editorial review Board of *Reality*, and is a Diplomat of the American Board of Oral Implantology/Implant Dentistry, the International Congress of Oral Implantologists and the American Society of Osseointegration. He is a Fellow of the American Academy of Implant Dentistry and received his Mastership in the AGD He can be reached at allquestions@smilecreator.net or 248-646-8651.