

IMPLANTS

Maintaining Facial Bone During Extractions

INTRODUCTION

As implant dentistry becomes more routine for replacement of nonrestorable teeth, it becomes imperative to maintain facial bone and interseptal bone, when possible. Traditional extraction techniques require tearing of the periodontal ligament with a periosteal elevator and a periosteal elevator, followed by forceful removal of the tooth from the socket using traditional techniques of buccal-palatal motion and/or "figure 8" movements. This process places incredible stress on the surrounding root structure and bone, which can often result in a fracture of the root or the facial plate of bone.

This is especially true with teeth that have been restored with crowns or veneers. We want to maintain the integrity of the existing porcelain work. Emergence profile, especially in the aesthetic zone of the maxillary anterior region, should be understood prior to any surgical intervention. Aesthetics in this region can be predictably completed when atraumatic extractions are performed and the viable surrounding hard and soft tissues are maintained. Forces created by conventional extraction techniques can make immediate placement of dental implants improbable.¹

There is also a psychological effect on our patients from trauma resulting from extractions. The idea of removing a tooth can be difficult for many patients, and this negative emotion is compounded by loss of a tooth in the front of the mouth or in the aesthetic zone.

CASE REPORT

Diagnosis and Treatment Planning

Our patient presented with a nonrestorable maxillary right canine that required extraction. Since the patient had under-



*Richard Golden,
DDS*



*Timothy Kosinski,
DDS*

gone previous implant therapy, she was aware of the benefits that this treatment could provide. The canine tooth had been treated previously with root canal therapy and a post and crown. The endodontist determined that the root structure of the tooth had fractured, requiring extraction (Figure 1). The teeth adjacent to the canine were moderately periodontally involved, although stable, with crowns in place. Tissue irritation and slight malposition of the fractured maxillary cuspid tooth was noted (Figure 2). Care would need to be taken to avoid dislodging the neighboring teeth and to prevent damage to any adjacent porcelain.

The treatment plan, agreed upon by our patient, was to atraumatically extract the tooth, create a socket with all the walls intact, graft the site, and then place an immediate dental implant.

Clinical Protocol

The patient presented with a challenging extraction due to the presence of very thin facial bone. It would be critical to remove the tooth as atraumatically as possible to preserve the bone and to avoid damaging any adjacent porcelain. After local anesthesia (one carpule of Septocaine articaine hydrochloride 4% and epinephrine 1:100,000 [Septodont]) was administered in conjunction with the Vibraject system (Golden Dental Solutions) (Figure 3) used to distract the patient from any discomfort from the injection. The motor vibrates the syringe, causing the needle to vibrate, where the light pressure of a Vibraject injection is carried rapidly to the brain on thicker, more insulated nerve tissues. By contrast, the prick of the needle travels on thinner nerve tissues, arriving too late for the brain to register the sensation. It was decided that the tooth would be extracted utilizing the Physics Forceps (Golden

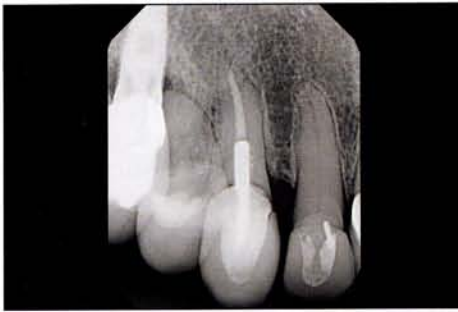

Figure 1. Preoperative radiograph of a nonrestorable maxillary right canine, requiring extraction. This tooth previously had root canal therapy and a post and crown.

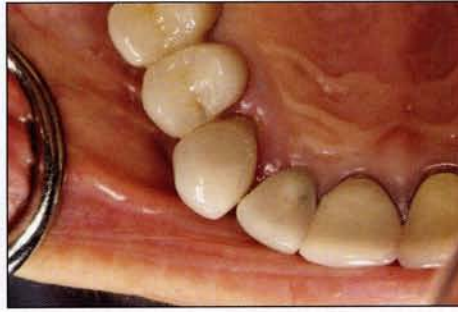

Figure 2. Preoperative image of the surgical site, showing tissue irritation and slight malposition of the fractured maxillary cuspid tooth.

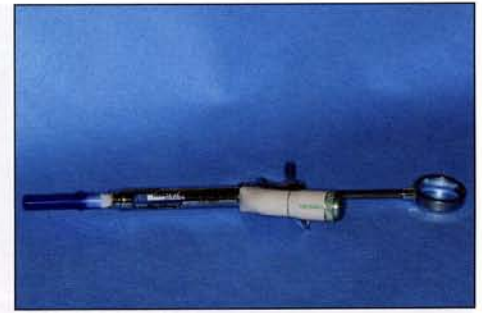

Figure 3. VibraJect (Golden Dental Solutions) was used to distract the patient and make an injection more comfortable.

Dental Solutions). The Physics Forceps design and associated technique eliminates not only the physical difficulty of removing teeth throughout the mouth; it also makes the process much easier and positive for the patient. The biomechanical design of the instrument reduces stresses placed on fragile root structure, helping maintain the facial plate of bone. When interseptal bone and the facial plate are maintained, the entire process of grafting and placing an immediate dental implant becomes more predictable.

The Physics Forceps is designed to work like a modified first-class lever. There are 2 parts of the instrument that consist of 4 instruments in total; one for the upper right, upper left, upper anterior, and a lower universal. The working component is referred to as the "beak." The beak is a flat plate that engages the palatal or lingual aspect of a tooth, 1.0 to 3.0 mm subgingivally. The root structure should be engaged as far down the root as possible. The second component of the instrument is the "bumper," which acts as a fulcrum. The bumper is engaged as high up or down the vestibule as possible. This bumper does not create any stress on the facial bone when used properly; no squeezing is done and only the wrist is used in an arch motion. The instrument is uniquely designed to allow tension to be placed on the periodontal ligament and to achieve excellent leverage. This tension results in the physiologic release of an enzyme by the body that breaks down the periodontal ligament over a short period of time. This process may take 20 seconds, or up to one to 4 minutes, depending on the tooth and surrounding bone structure of the patient. The clinician must be patient, as the technique will feel like nothing is happening since none of the usual operator movements are employed. With the breakdown of the periodontal ligament, the tooth will

release or "pop" out of the socket in an upward and outward motion, mirroring the arch form of the head of the instrument. This innovative instrument allows tooth dislodgment with little or no pressure, simply utilizing leverage. The handles are never squeezed like a conventional forcep; rather they are held lightly in the hand, and the wrist is rotated to simply create tension on the palatal aspect of the root (Figure 4). There is no forearm, bicep, or shoulder pressure used. The handles simply allow the beak to engage the root structure without slipping off.

During a short time of constant tension, the root will disengage or pop from the socket incisally and facially. Although the facial bone may expand slightly, the movement of the tooth out of the socket is not straight facial, but rather up and out of the socket. This allows for maintenance of the facial plate of bone, when the instrument is used correctly. One of the biggest misconceptions of this innovative technique is that it is a "forcep" as the names implies, when in fact it is a *lingual elevator*. Our muscle memory wants us to use it like a traditional forcep, and thus, we tend to squeeze the handles and create undue stress on the root and facial bone. To use this instrument properly, we must remind ourselves not to treat the instrument like a conventional forcep to achieve success.

Once the tooth disengages from the socket, a tooth delivery instrument (such as a pincer-type forcep) is used to remove the root in total from the socket atraumatically (Figure 5). In this case, the long canine root was removed from the socket, maintaining the facial plate of bone, the interseptal bone, and interdental papilla (Figure 6).

Patients' response to the Physics Forceps technique is nothing short of amazement. Often times, patients will say something like, "You're kidding! You're

done?" This creates a positive experience for patients, providing outstanding marketing for the practice.

These instruments are ideal any time bone needs to be preserved during extractions, as in this case demonstration, where we wanted to immediately graft and place a single dental implant in the maxillary right canine area.

Following the extraction, we had a socket with the walls intact (Figure 7). The facial plate of bone was intact, thus creating a socket shaped liked a cereal bowl. The quadrant CBCT (Green PaX-i3D [Vatech America]) (Figure 8) shows the socket site and the maintenance of the facial plate of bone in this cuspid area. (Note how thin that facial plate is and that it was maintained predictably by the use of the Physics Forceps.)

Following the extraction, it becomes a routine procedure to place grafting material into this site. Because the socket itself is shaped like an egg, and the implants we currently use are round, it is important to add some grafting material to fill any void greater than 2.0 mm.² This allows the body to respond to the healing process, and for osteoclasts to eat away the bone surrounding the implant, while simultaneously, osteoblasts lay down new bone. When grafting any site, we must consider the materials to be chosen. Autogenous bone, the patient's own bone, is the gold standard for grafting materials. However, this would require harvesting bone from a secondary site, which requires a second surgery. Allograft is made of bone from another human. It may be mineralized, meaning the bone minerals are not processed away, or demineralized, meaning the bone materials are processed out of the bone. Mineralized bone takes a bit longer to resorb and be replaced. Oftentimes, a combination of mineralized and demineralized bone is used to spread out the time of resorption and replacement. Cortical bone is the

hard bone chips; this bone can be demineralized or left with the minerals present, and it takes longer to resorb. Cancellous bone is porous and always presented mineralized. The allografts we commonly use are a combination of cortical-cancellous, mineralized-demineralized material. Other combinations are available, depending on the time desired for the regeneration of bone. Regardless of the material used, all of the allograft is eventually replaced by the patient's own bone and is an effective and safe means of creating bone. Alloplastic materials are often referred to as "synthetic" products. There are several types, including tricalcium phosphate, glass, and hydroxyapatite.²

In this case, the grafting was completed after placing an immediate implant. Once the tooth was atraumatically removed, the subsequent osteotomy burs were used to create a space for the immediately placed dental implant. The Implant Direct Legacy 3 technique (Implant Direct) was used here. A 2.2-mm pilot bur was used to engage the bone palatal to the socket, approximately 3.0 mm palatal to the facial aspect of the adjacent teeth (Figure 9). This protected the thin facial bone from becoming dislodged and provided room for a custom abutment and a properly designed aesthetic implant-retained crown. In this case, the site was prepared for a 3.7-mm diameter by 13-mm long Implant Direct Legacy 3 implant (Implant Direct).

Prior to the implant being threaded into the prepared osteotomy site, an EpiGuide Synthetic (Golden Dental Solutions) long-lasting membrane was cut to size and engaged onto the facial plate of bone at least 2.0 mm (Figure 10). Any graft must be protected from invagination of the epithelium tissue, as bone integrates much slower than tissue formation. One must consider the placement of a membrane or barrier to protect our graft and allow the body to replace this material. Any membrane must be properly positioned, engaging at least 2.0 mm of facial bone and 2.0 mm of palatal bone. This will ensure that the membrane does not disengage too fast.

An allograft putty, in a 1.0-cc syringe with cortical bone chips (GoldOss Allograft DBM Crunch Putty [Golden Dental Solutions]), was squirted into the socket site prior to implant placement (Figure 11). It was firmly packed, but not condensed, into the socket. Remember, the particle sizes vary from 250 to 1,000 μm , allowing for resorption to occur throughout time. After the graft was placed, an Implant Direct Legacy 3 threaded implant was placed (Figure 12). It was positioned at a proper

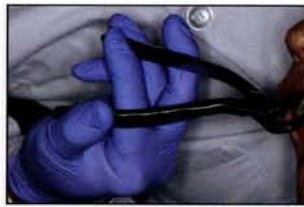

Figure 4. Atraumatic extraction with the Physics Forceps (Golden Dental Solutions). Using the proper hand position and hold are a must when utilizing the Physics Forceps technique.

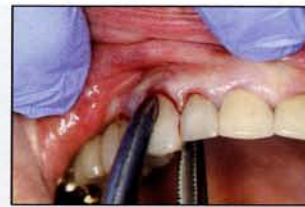

Figure 5. The tooth was delivered from the socket with a pincer-type instrument (EZD [Golden Dental Solutions]) as the Physics Forceps are not designed to remove the tooth all the way from the socket but simply to elevate the tooth or release the periodontal ligaments.

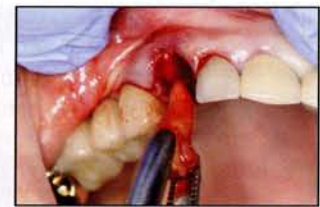

Figure 6. The broken-down root was easily removed from the socket.

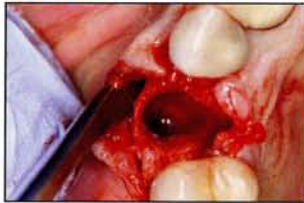

Figure 7. A flap was reflected in preparation for graft and immediate implant placement, as well as to demonstrate facial bone.

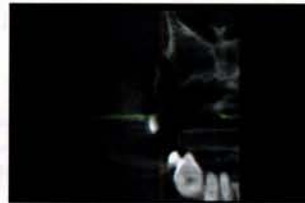

Figure 8. CBCT imaging (Green PaX-i3D [Vatech America]) was utilized to visualize the bone. Note that the bone, in preparation for an immediate implant placement, was intact and not damaged during the Physics Forceps extraction.

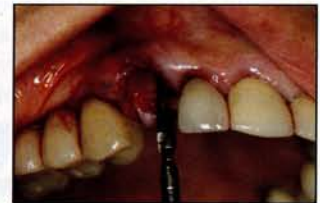

Figure 9. Implant Direct Legacy 3 technique (Implant Direct) was used. A 2.2-mm pilot bur engaged the bone palatal to the socket (approximately 3.0 mm palatal to the facial aspect of the adjacent teeth).

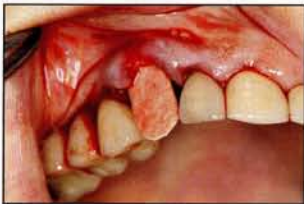

Figure 10. EpiGuide Synthetic (Golden Dental Solutions) long-lasting membrane was cut to size and engaged onto the facial plate of bone at least 2.0 mm.

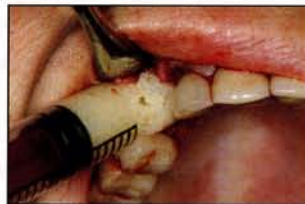

Figure 11. GoldOss Allograft DBM Crunch Putty (Golden Dental Solutions) with cortical chips in 1.0-cc syringe was utilized.

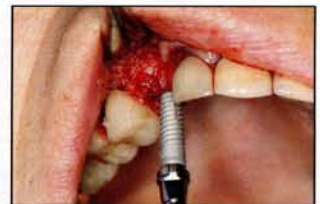

Figure 12. A 3.7-mm diameter by 13-mm long Implant Direct Legacy 3 implant (Implant Direct) was utilized in this case.

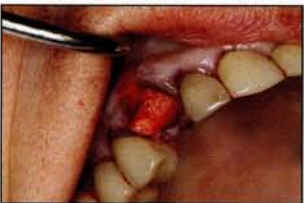

Figure 13. Membrane was tucked securely in place at least 2.0 mm onto solid bone.

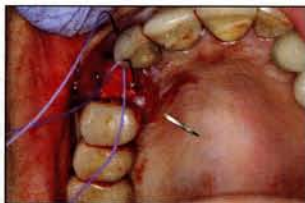

Figure 14. Vilet 3-0 FS-2 reverse cutting sutures (Implant Direct) were utilized going from the inside toward the lingual, while not engaging the membrane.

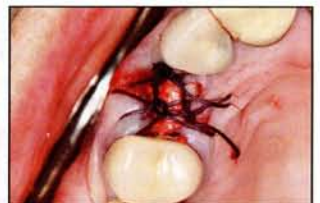

Figure 15. Postoperative view of surgical site.

angulation slightly apical to the coronal aspect of the socket, and slightly palatal to the facial aspect of the adjacent teeth. It was torqued to 25 Ncm, engaging solid bone on the palatal aspect of the socket and apically. The membrane was then rolled over the socket site and tucked into the palatal tissue, again at least 2.0 mm on bone surface

(Figure 13). This ensured that the membrane would not move during the healing period, providing predictable results.

Although the membrane was ideally positioned to prevent easy movement, it was sutured into place using Vilet 3-0 FS-2 reverse cutting sutures (Implant Direct) made of a polyglycolic acid material. This

material takes time to resorb; does not wick bacteria; is easy to see; and is resorbed by saliva action, dissolving into a water base (Figure 14). The final suturing was done to maintain the interdental papilla and to close the surgical site well; the facial contours of the bone were ideal with no defect or invagination noted (Figures 15 and 16). The sutures were removed in approximately 7 days. The membrane would eventually resorb, leaving osteoid on the crestal aspect of the socket. Osteoid is a precursor to bone. The epithelium never has a chance to invaginate into the socket surgical site as shown 2 weeks postoperatively (Figure 17). Osseointegration was allowed to progress for a minimum of 4 months, after which the site was opened and an impression made of the internal design of the implant using conventional implant impression techniques.

CLOSING COMMENTS

The critical aspect of immediate dental implant placement is the atraumatic extraction of teeth, maintaining as much bone structure as possible to allow for ini-

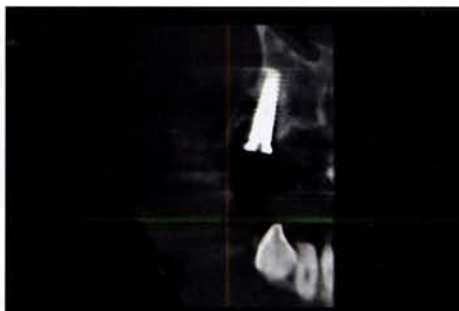

Figure 16. Green CT (VaTech America) post-operative view of surgical site and dental implant

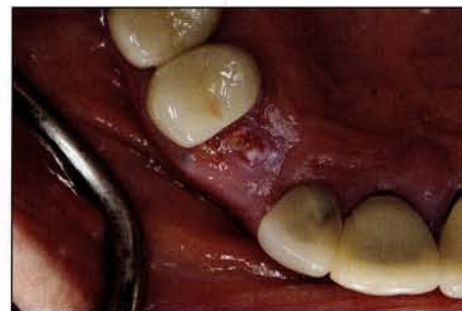

Figure 17. Two-week postoperative image of the site.

tial stability of the dental implant, and proper healing of the surgical site. When considering dental implant techniques, the practitioner must be aware of the most noninvasive instruments and associated techniques available to ensure optimal functional and aesthetic results. Maintenance of facial contours of bone and proper grafting techniques is a must. When grafting, the use of a properly positioned, high-quality membrane or barrier must be understood. The membrane must

be engaged so it is not pushed out by the epithelium. Predictability of our extraction, grafting, and implant placement techniques should be in the forefront of our treatment goals. When done well, our patients receive treatment that is relatively nonstressful, with minimal discomfort, and the aesthetic contours of tissue and bone can be well maintained. This makes creation of an implant restoration aesthetic, even in the challenging aesthetic zone. ♦

References

1. Testori T, Bianchi F. Ideal Implant Positioning in a Maxillary Anterior Extraction Socket. *Academy News* (Academy of Osseointegration). 2003;14(2):1,8. osseo.org/assets/pdf-files/news/AONewsVol%2014-2.pdf. Accessed on February 19, 2015.
2. AlGhamdi AS, Shibly O, Ciancio SG. Osseous grafting part 1: autografts and allografts for periodontal regeneration—a literature review. *J Int Acad Periodontol*. 2010;12(2):34-38.




Dr. Kosinski received his DDS from the University of Detroit Mercy Dental School and his Mastership in biochemistry from Wayne State University School of Medicine. He is an adjunct clinical professor at the University of Detroit Mercy School of Dentistry and serves on the editorial review board of *REALITY*, is the information source for aesthetic dentistry for the *Michigan Dental Association Journal*, and is the editor of the Michigan AGD's *Impact*. He is currently immediate past president of the Michigan AGD. A Diplomate of the American Board of Oral Implantology/Implant Dentistry, the International Congress of Oral Implantologists, and the American Society of Osseointegration, he received his Mastership in the AGD, and is also a Fellow of the American Academy of Implant Dentistry, the American and International Colleges of Dentists, and the Academy of Dentistry International. He is a member of Omicron Kappa Upsilon and the Pierre Fauchard Academy. He has published more than 94 articles on the surgical and prosthetic phases of implant dentistry. He was a contributor to the textbooks *Principles and Practices of Implant Dentistry* and 2010's *Dental Implantation and Technology*. He was featured on Nobel Biocare's Nobelvision and lectures extensively. He was named University of Detroit Mercy School of Dentistry Alumni Association's "Alumnus of the Year," and in 2009 received the AGD's lifelong learning and service recognition. He can be reached at (248) 646-8651 or drkosin@aol.com.

Disclosure: Dr. Kosinski reports no disclosures.


Dr. Golden graduated from the University of Detroit Mercy School of Dentistry. He currently serves on its board of directors and is adjunct clinical professor at the school. He is a full-time practicing general dentist with a private practice in Detroit. He is the founder of the Golden Dental Centers group practice in Metro Detroit. He is the inventor of the Physics Forceps extraction system and associated technique as well as the founder of Golden Dental Solutions. He can be reached toll-free at (877) 987-2284 or via email at info@goldendental-solutions.com.

Disclosure: Dr. Golden is President of Golden Dental Solutions and the inventor of the Physics Forceps instruments.

IF WE HAVE IT, IT'S BECAUSE YOU NEED IT!™

 <p style="font-weight: bold; color: white;">Pilot Drill + Surgical Guide</p>	 <p style="font-weight: bold; color: white;">Predictable Atraumatic Extractions</p>
 <p style="font-weight: bold; color: white;">Improved Crown & Bridge Removal</p>	 <p style="font-weight: bold; color: white;">Pain Free Injections</p>

Visit Our Website to Learn More!



877.987.2284

GoldenDentalSolutions.com