

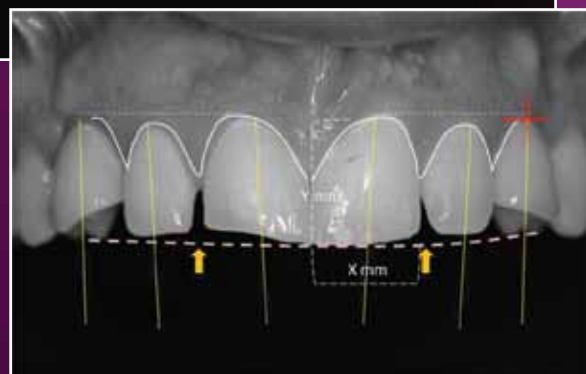
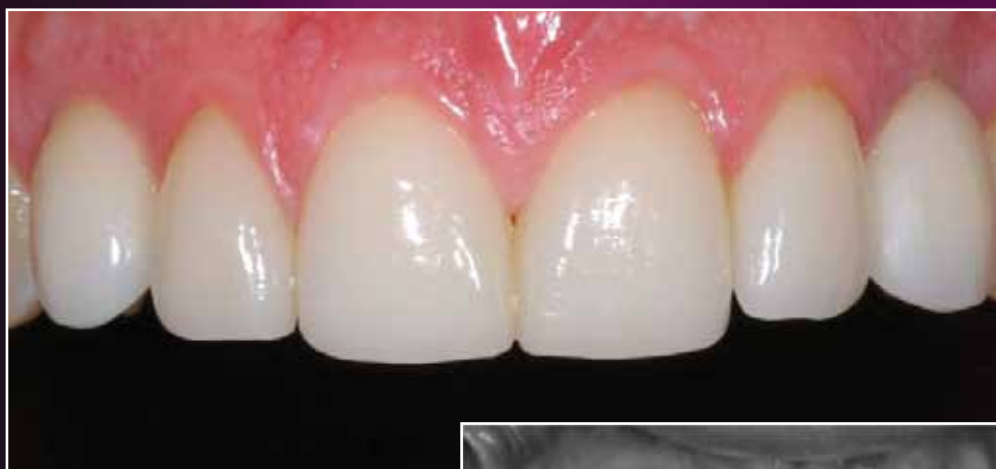
Inclusive®

Restorative Driven Implant Solutions

Vol. 1, Issue 3

A Multimedia Publication of Glidewell Laboratories



Guiding, Evaluating Implant Esthetics

by Dr. Lyndon Cooper Page 6



Priced to Sell: Dental Fee Psychology

by Dr. David Schwab Page 18



The Science Behind BruxZir® Solid Zirconia

by Robin Carden Page 20



Digital Treatment Planning for Single Posterior Implants

by Dr. Timothy Kosinski Page 27



*Introducing
whatimplantisthat.com
Implant Identification
Made Easy Page 15*

Digital Implant Treatment Planning

Restoration of Maxillary Posterior Single Teeth



Go to inclusivemagazine.com for more photos and to earn CE credit on this article.

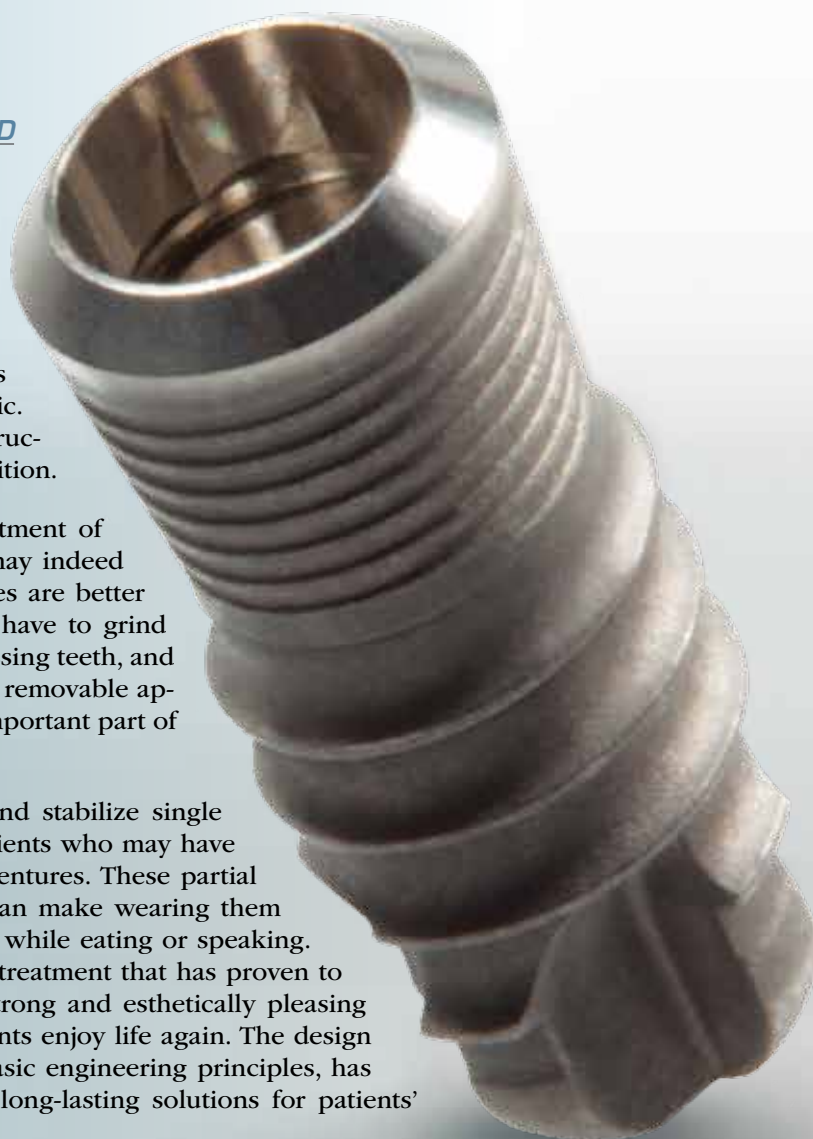


*Article and photos
by Timothy F. Kosinski, DDS, MAGD*

Dental implants have undergone many positive advances in recent years. Our successes have dramatically increased, to the point where implant dentistry has become a constructive and simple alternative to conventional dental procedures. When a patient is missing one or more teeth, single dental implants prove functional and the final restorations esthetic. The newest materials can predictably match the structure, contour and lifelike qualities of natural dentition.

Partial dentures and bridges have been the treatment of choice in dentistry for generations. The results may indeed be acceptable, but the newest implant alternatives are better and less traumatic to the patient. We no longer have to grind down healthy tooth structure to replace single missing teeth, and patients no longer have to bear the restraints of a removable appliance. Today, dental implants are a viable and important part of tooth replacement in our practices.

The use of dental implants to support, retain and stabilize single crowns greatly improves the quality of life in patients who may have been deemed candidates for removable partial dentures. These partial appliances can be difficult to wear. Sore spots can make wearing them miserable, and they can move around the mouth while eating or speaking. It is intuitive that replacing missing teeth with a treatment that has proven to have an outstanding prognosis, is functionally strong and esthetically pleasing is a better option. Dental implants can help patients enjoy life again. The design of our modern dental implants, which follows basic engineering principles, has allowed the implant dentist to create beautiful, long-lasting solutions for patients' dental problems.



However, there are still concerns with any surgical procedure, especially in the sinus areas or in bone where nerves are located. These concerns have popularized the newest concepts in implant dentistry. We are now able to utilize CAD/CAM computer software to virtually place dental implants using CT scanning software to visualize the patient's entire oral anatomy in three dimensions, which takes only a few minutes. The reluctance to place implants in certain anatomic areas is eliminated with the virtual evaluation of anatomy and placement of the implants in question. We are now certain of ideal placement or have the ability to abort the case or consider additional procedures before touching the patient.

The information from a CT scan can be used by several scanning software programs. For this case we selected Simplant® (Materialise Dental Inc.; Glen Burnie, Md.). This system has an open architecture, which allows us to virtually choose the desired implant and position it based on the vital anatomy. Digital treatment planning is proving to be a cost-effective solution to assist the implant dentist in planning an esthetic final result and minimize any surgical challenges he or she may face. Patient acceptance is improved because concerns the individual may have can be addressed in a precise manner.

CT technology is based on planning algorithms used clinically for many years. CT scans and 3-D planning software can greatly improve our predictability and safety. This technique can be used for single-tooth edentulous spaces, like in the clinical case that follows, partially edentulous spaces, fully edentulous maxillary and mandibular overdenture cases, or fully edentulous maxillary and mandibular full-arch permanent restorations. The surgical cases are, therefore, driven by the final esthetic and functional result. It is critical to make sure that the final tooth contours are established prior to any surgical intervention. Placing the dental implants in the jaw before understanding tooth position and the final result is a big mistake.

CT planning placement systems, like Simplant, provide a high level of comfort and safety for the patient by reducing surgical and restorative time. This is done by utilizing an accurate three-dimensional plan prior to implant placement. There are obvious advantages, including: easy visual understanding for clear case presentations to the patient, reduced surgical chairtime, reduced restorative chairtime in certain cases, reduced stress for the clinician and the patient, the avoidance of surprises during surgery, implants that are placed optimally for long-term implant and prosthetic success and, most importantly, an improved esthetic result.

Typically, a scan appliance should be fabricated by the lab. This appliance shows the ideal prosthetic position of the teeth in the planning software. In a single implant case, a CT scan alone can be used to diagnose and

virtually place the implant of choice. The planning software allows you to drop virtual teeth into the edentulous area.

The surgical placement of dental implants can be done in a conventional manner using the information gathered in diagnosis using the CT image or a surgical guide created to help direct the implants in the ideal position. Based on the amount of attached gingiva, these cases can often be completed through a flapless procedure.

Our patient in the case that follows is a 44-year-old female with several dental problems. The right and left maxillary first molars had been extracted years earlier. The mandibular arch will be restored with grafting and implants in the future. The main objective was to establish a correct occlusal plane relationship and improve the esthetics.

Our choice of implants was SybronPro XRT™ dental implants (Sybron Dental Specialties; Orange, Calif.). The SybronPro XRT implant design incorporates innovative microthreads, a mount-free delivery system and self-taping threads. An internal octa or hex pattern allows for great stability of the platform-switching abutments. Here, a 4.8 mm crestal width, 4.1 mm body, 9 mm tall implant was used in the tooth #3 area. The determining factor in shape and size of the implant was based on the height and width of bone below the sinus. If less bone had been available, a sinus lift may have been necessary. The edentulous area of tooth #14 was an ideal place for a 4.1 mm by 9 mm internal hex implant. Two different implants were used in contralateral positions to describe the surgical technique and final implant restorations of each design.

Final restoration consisted of a titanium abutment and cemented crown. Three different types of crowns were fabricated by the dental laboratory for comparison purposes, including esthetic and durable PrismaTik CZ™ (zirconia coping with porcelain veneer), conventional porcelain fused to metal and BruxZir® Solid Zirconia. It was determined that the PrismaTik CZ crown was the most esthetic and would be durable. The abutment screws were tightened to 25 Ncm, the screw access openings sealed and the crowns cemented into place.

CONCLUSION

Implants provide an excellent option for restoring missing single teeth. CT scans and planning software prove invaluable in treatment planning. This case highlights the technique to restore missing posterior maxillary teeth utilizing a minimally invasive surgical procedure leading to an esthetic, functional prosthetic result.

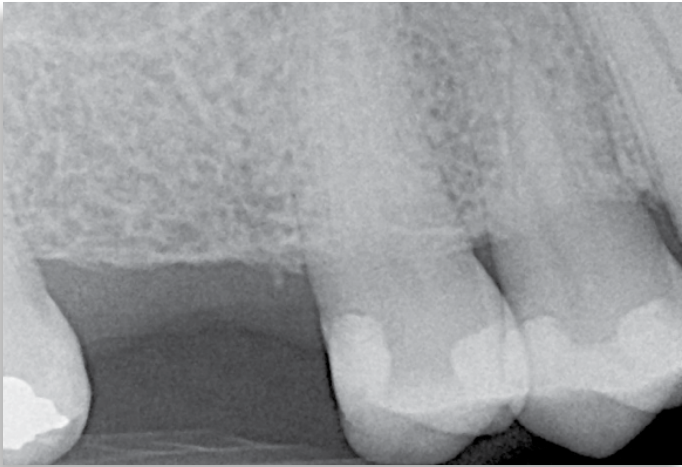

Figure 1: Periapical of edentulous maxillary right first molar area. How much vertical and height of bone do we really have?

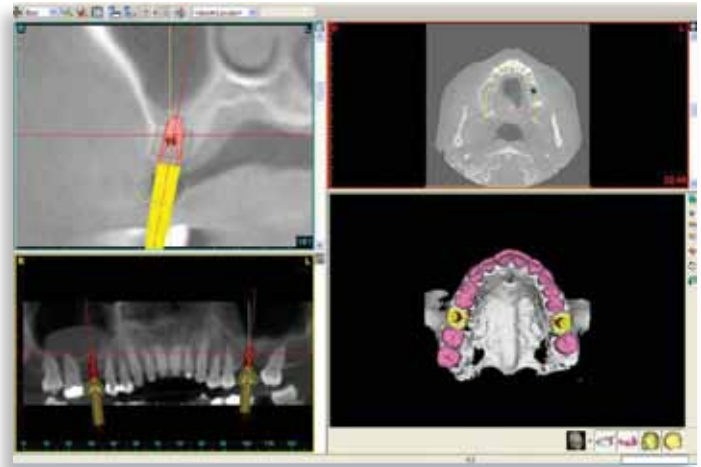

Figure 2: CT digital plan illustrates panoramic cross-sectional and axial views, as well as three-dimensional rendering of the patient's maxilla. Simple panoramic radiographs or periapicals do not give the 3-D image achieved with CT scanning. Note: The patient had a large polyp in the maxillary right sinus. The sinus membrane is slightly thickened on the left side.

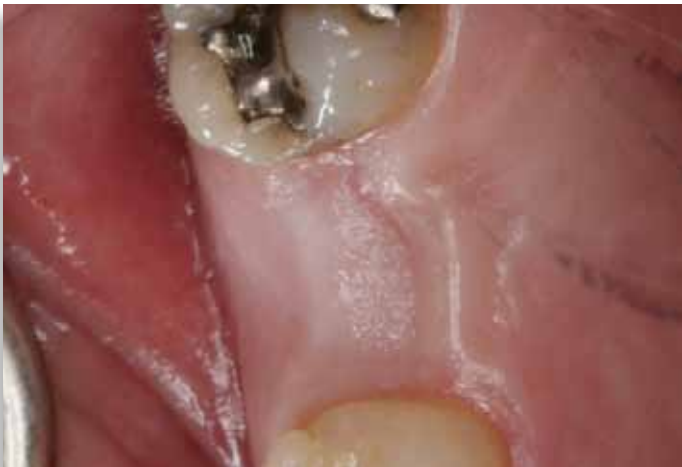

Figure 3: Occlusal view of tooth #3 area. It appears clinically that we have adequate width of bone, but the CT gives us an exact interpretation of the amount of bone present.

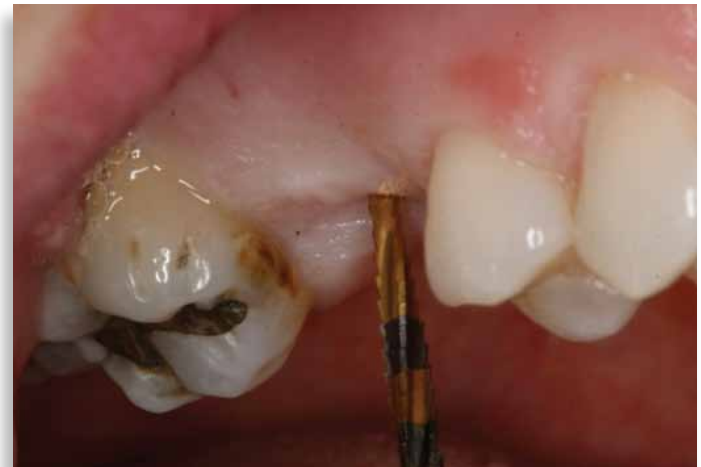

Figure 4: The Sybron implant system is simple and precise. The first drill used to initially determine angulation is the Lindemann Guide. This is a very sharp drill with a point. It also allows for lateral positions, as it also cuts on its side.

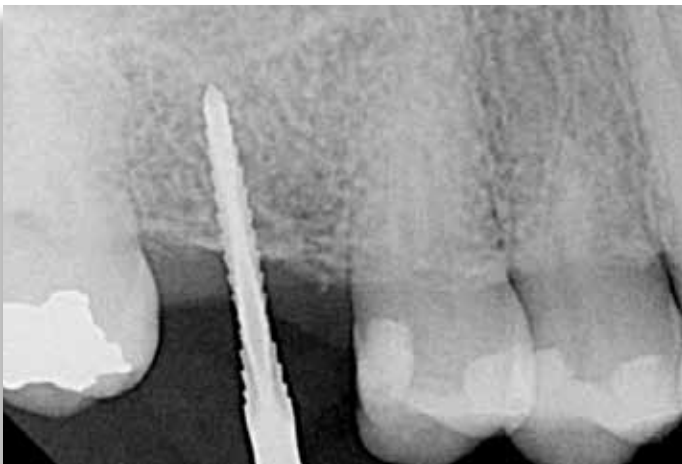


Figure 5: A digital radiograph is taken to determine angulation of the primary drill.

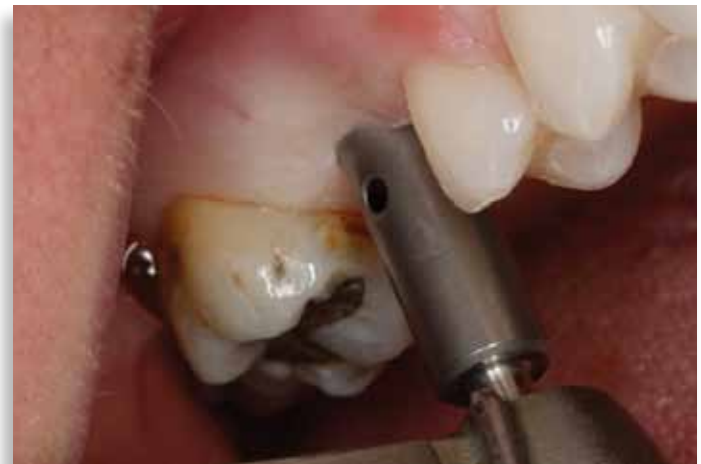

Figure 6: A sharp tissue punch blade removes soft tissue at the surgical site and eliminates the need for a full thickness flap. Sutures will not be required after implant placement.

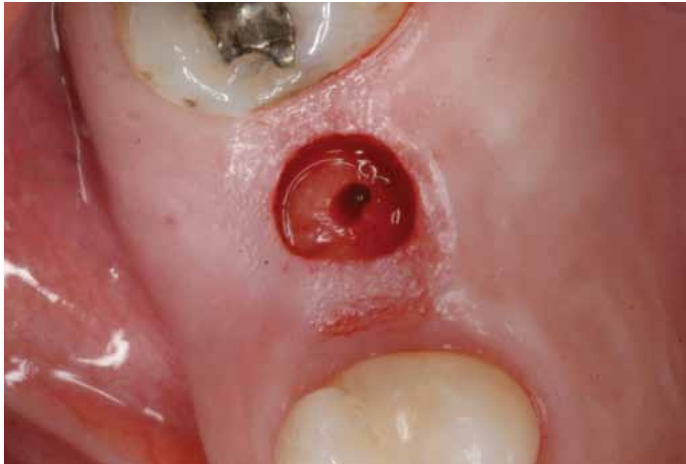


Figure 7: The soft tissue is removed with a curette.

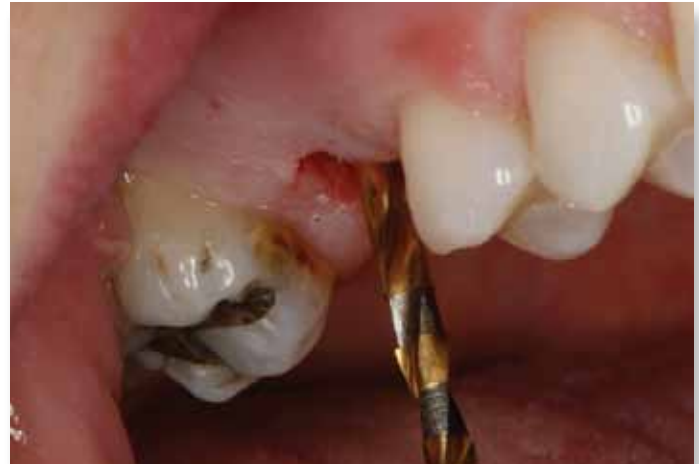

Figure 8: The 2.2 mm diameter Twist Drill is used to establish depth, followed by the 3.3 mm and 4.1 mm Twist Drills. The black lines are clearly delineated: 7 mm, 9 mm, 11 mm, 13 mm and 15 mm. Note the gingival was approximately 3 mm in height, so in determining a visual of how deep to place the implant, the 9 mm we want the implant to go into bone is added to the 3 mm of soft tissue height. Therefore, the line markings on the Twist Drill is visualized to 12 mm.

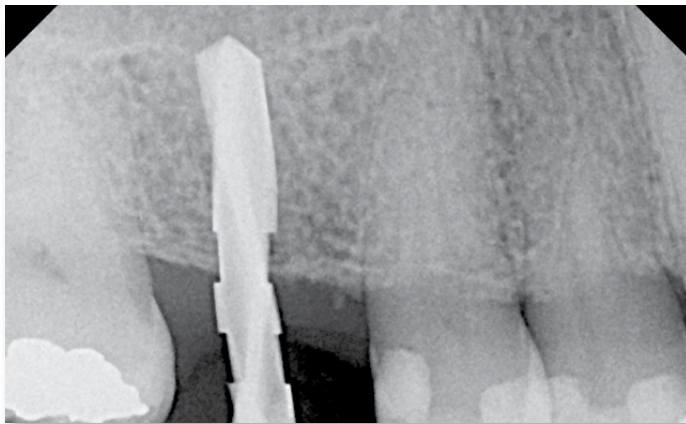


Figure 9: Radiograph of 3.3 mm Twist Drill in site. Note the notches of the drill itself. The first break is at 7 mm, the second at 9 mm. This is intended to be our final depth, just at the floor of the sinus.



Figure 10: The SybronPRO XRT Octa implant is picked up on the implant driver.

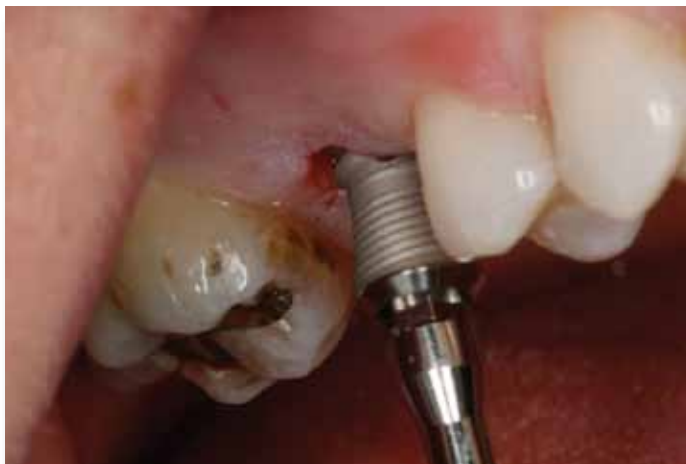

Figure 11: The motor is turned down to record 25 Ncm of torque. The implant is driven into the osteotomy site and stops when 25 Ncm of torque is achieved.

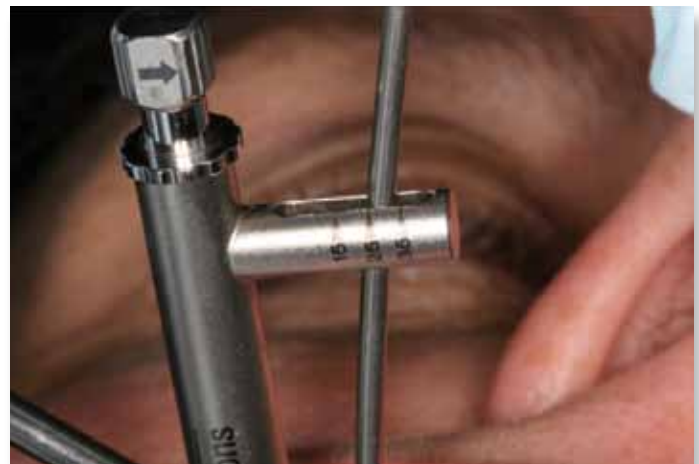

Figure 12: Final seating and the tightness of the implant in bone is accomplished with the torque wrench. The wrench is marked at 15, 25 and 35 Ncm. We easily achieved 25 Ncm of torque on this implant in the maxillary right first molar area.

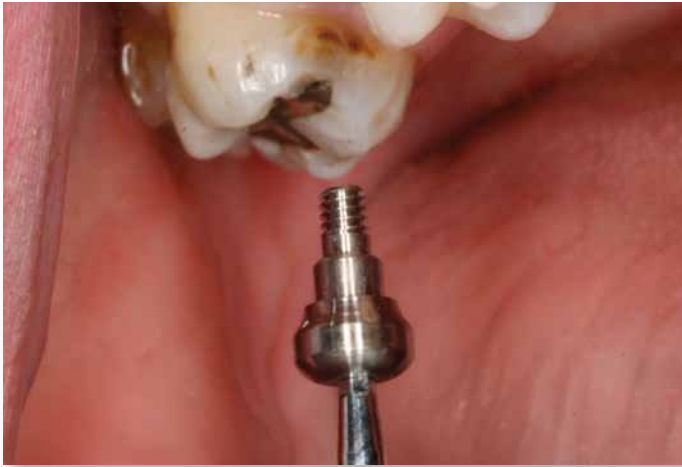

Figure 13: Either a cover screw or a taller healing abutment can be safely placed into the implant to allow for tissue healing.

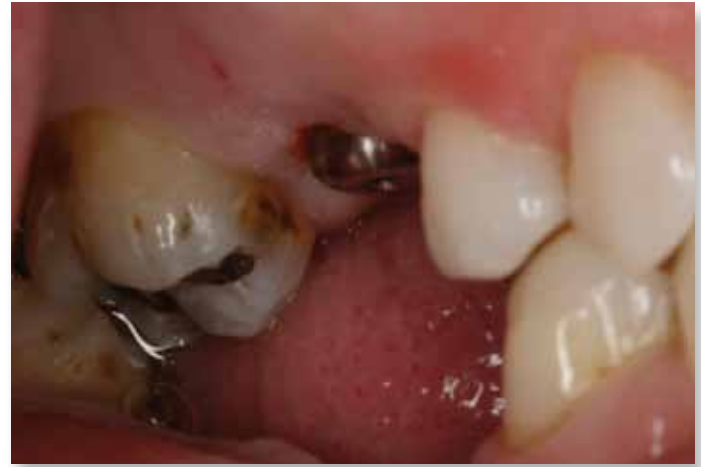

Figure 14: The healing abutment is tightened to 15 Ncm, which will prevent any loosening during the healing phase. Note there is no bleeding; no sutures were required. This is a very noninvasive therapy.

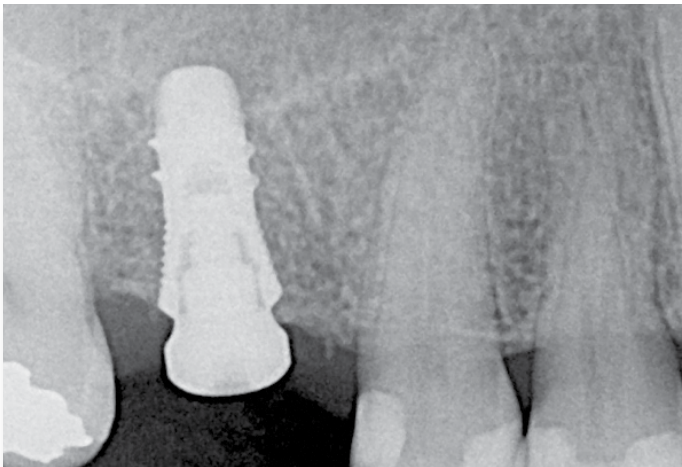


Figure 15: A radiograph of the Sybron Octa implant shows the position immediately after surgical placement. Note the platform-switching design of the healing abutment.

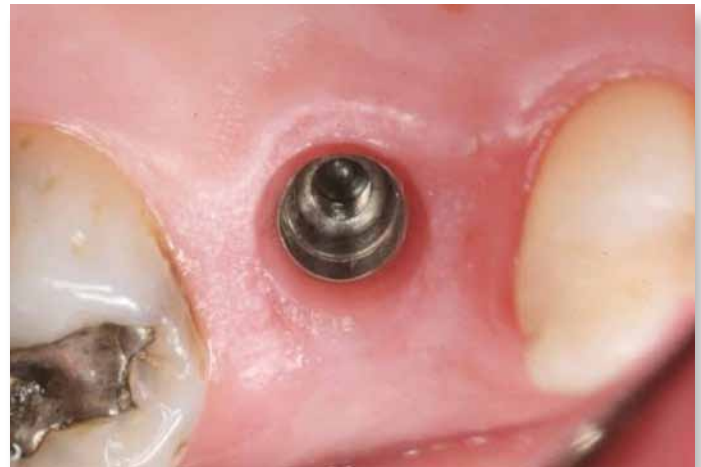

Figure 16: Tissue healed around the healing abutment after four months of integration. The patient had no symptoms and only took a Tylenol for discomfort the day of surgery. The healing abutment is removed from the implant. Note healthy gingival cuff created by the healing abutment.



Figure 17: A direct impression is planned. The impression system is a two-piece system with an octagon base that engages the internal design of the Sybron implant and a screw that threads it into position.

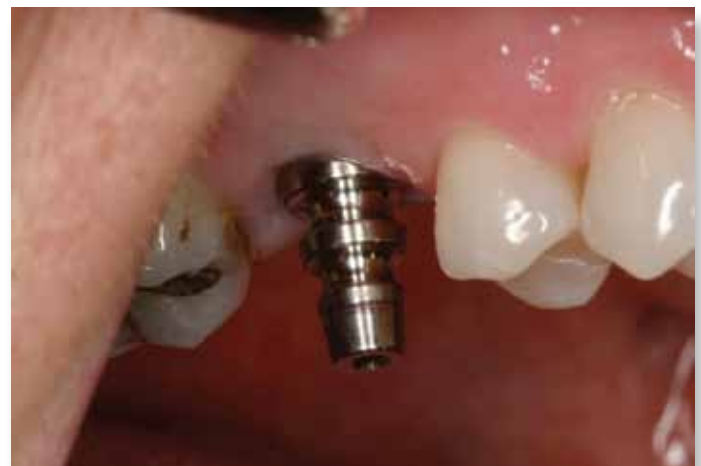

Figure 18: A hex driver is used to place the impression coping.

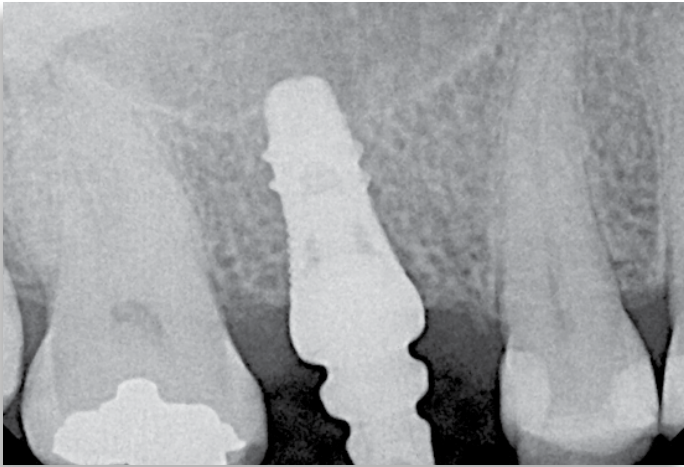


Figure 19: A radiograph is taken to ensure a complete seat of the impression coping. This is a mandatory protocol procedure to ensure the impression coping engages the implant completely.

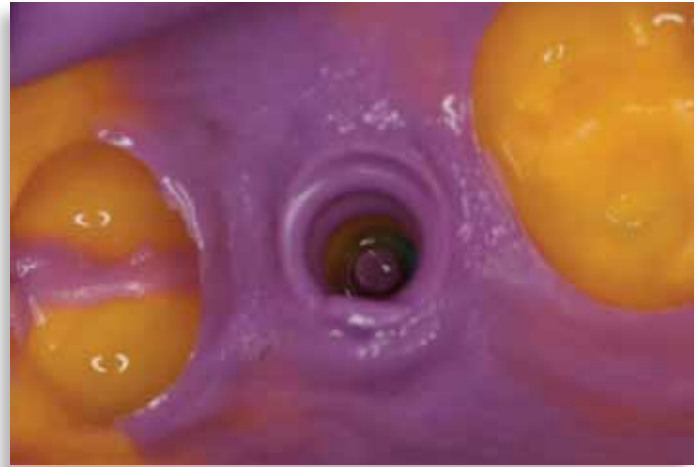

Figure 20: Note the clean contours of the impression. The impression coping must be retained properly in the impression to ensure a proper abutment and crown fabrication.



Figure 21: The impression coping is removed from the implant and mounted onto a laboratory implant analogue.

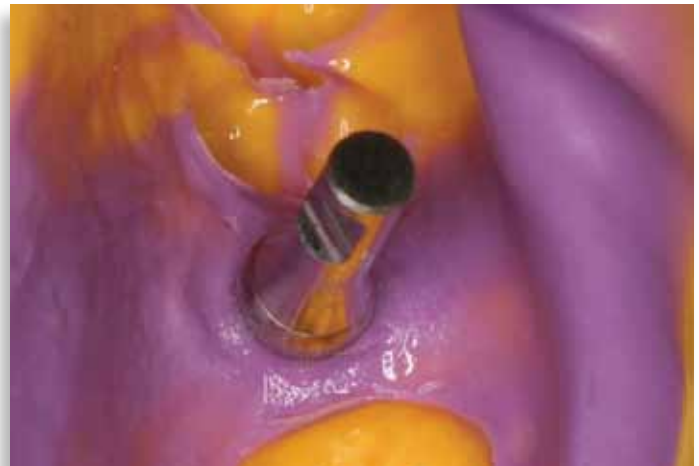

Figure 22: The head of the impression coping is resealed into the impression, a shade taken and the case sent to the lab.

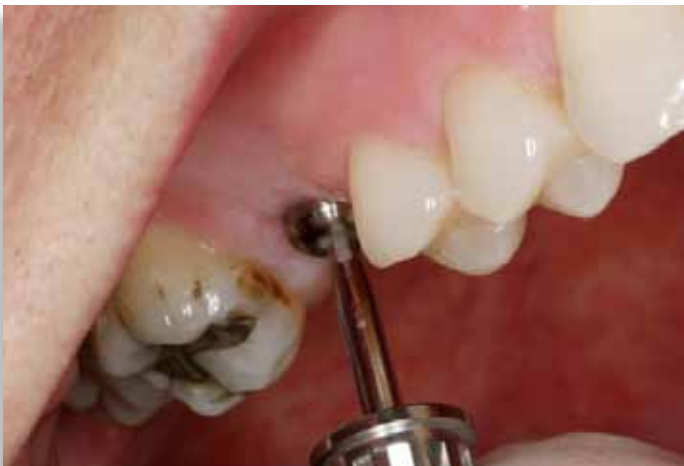

Figure 23: The healing abutment is replaced in the mouth while the dental laboratory makes a master cast using the implant analogue to fabricate the proper abutment and crown.

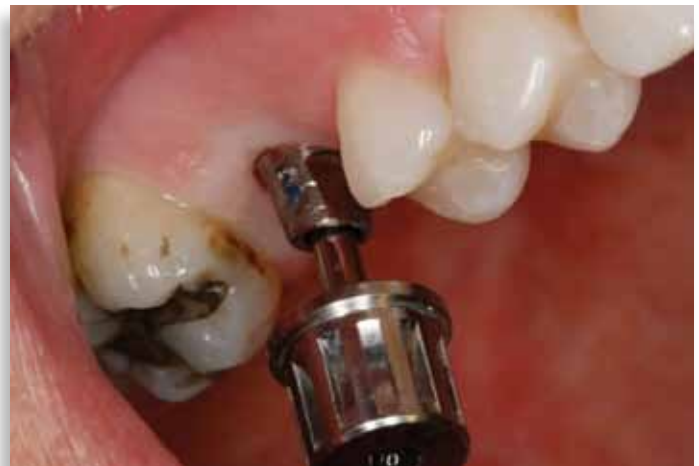

Figure 24: The healing abutment is removed. The prepared abutment is seated and the abutment screw tightened to 25 Ncm.

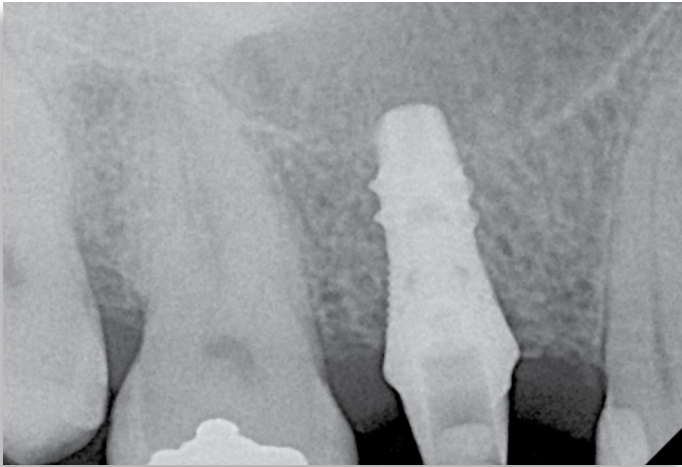


Figure 25: A radiograph is taken to ensure a complete seating of the abutment into the body of the implant.

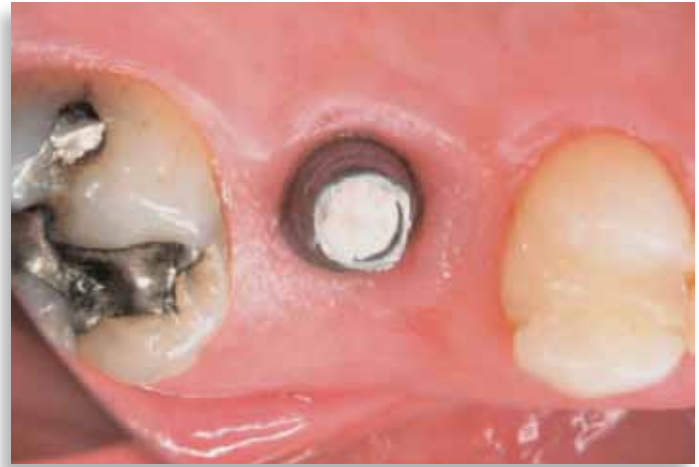

Figure 26: A piece of cotton or silicone is placed into the screw hole after tightening the abutment screw to the recommended torque. A little Cavit is used to cover the screw hole before crown cementation.

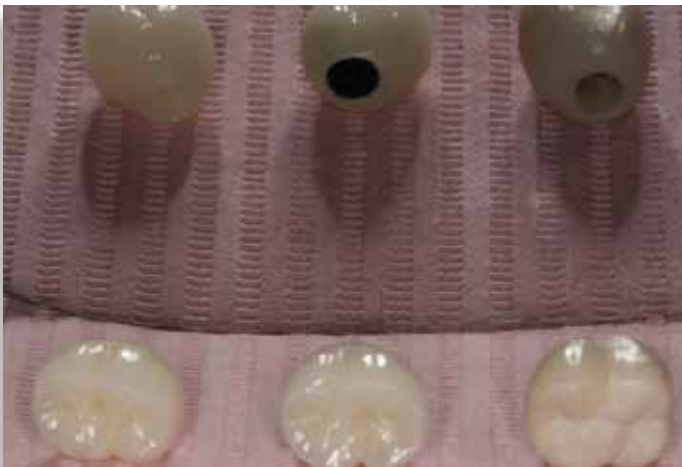

Figure 27: Three different designs and types of crowns can be fabricated by the dental laboratory: esthetic Prismatik CZ™, conventional PFM or durable BruxZir® Solid Zirconia. A Prismatik CZ crown was chosen for its esthetics and strength.

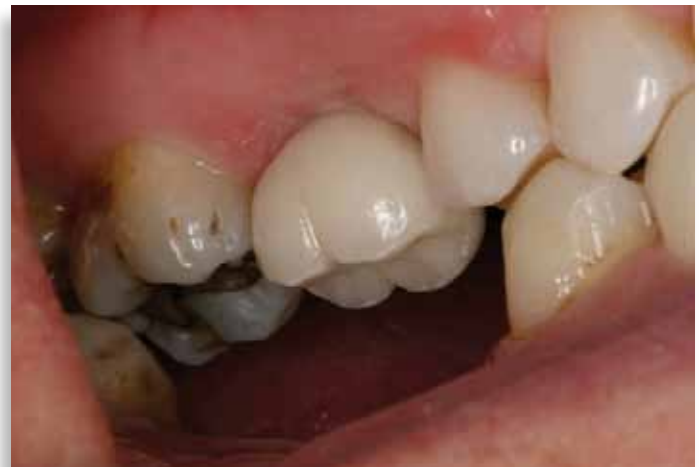

Figure 28: The Prismatik CZ crown is cemented into place.

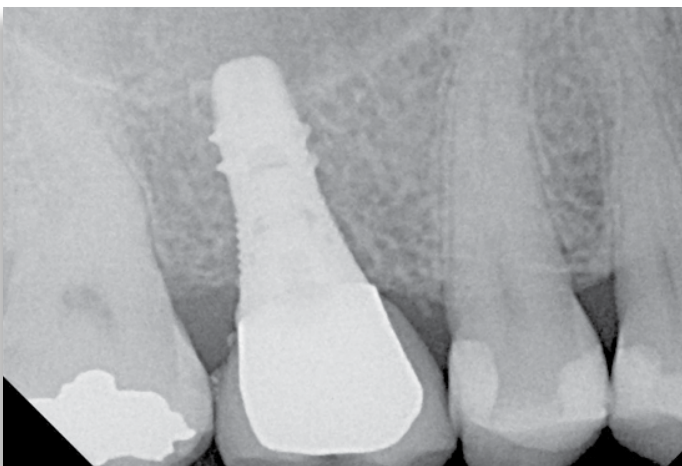


Figure 29: Final radiograph of implant-retained maxillary first molar cemented into place.

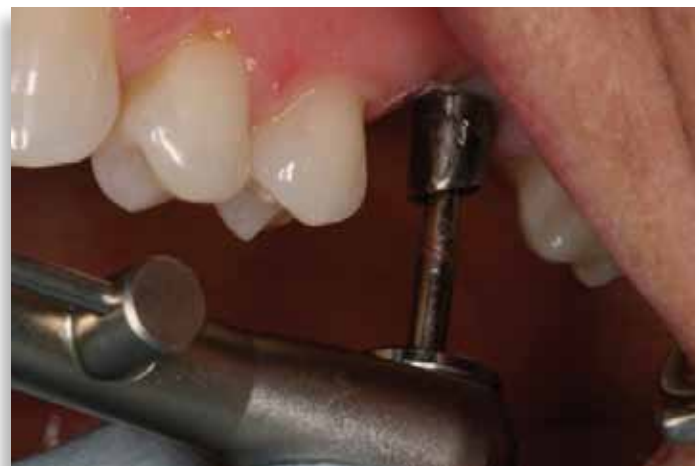

Figure 30: Delivery of the final prosthesis for tooth #14: The healing abutment is removed, the hex abutment is seated and the abutment screw tightened to 25 Ncm.

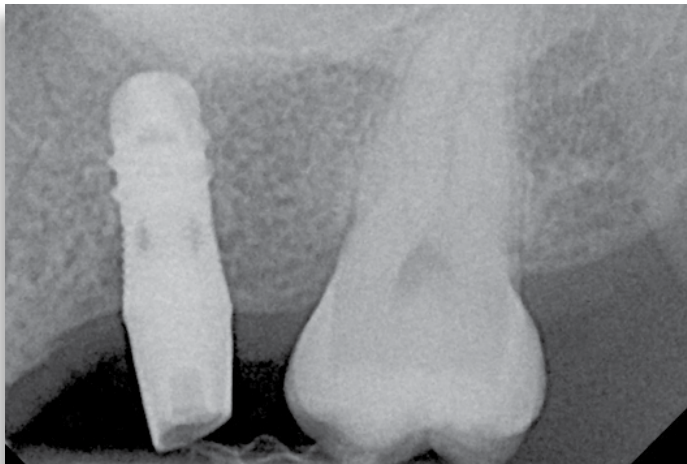


Figure 31: A radiograph is taken to ensure complete seating.

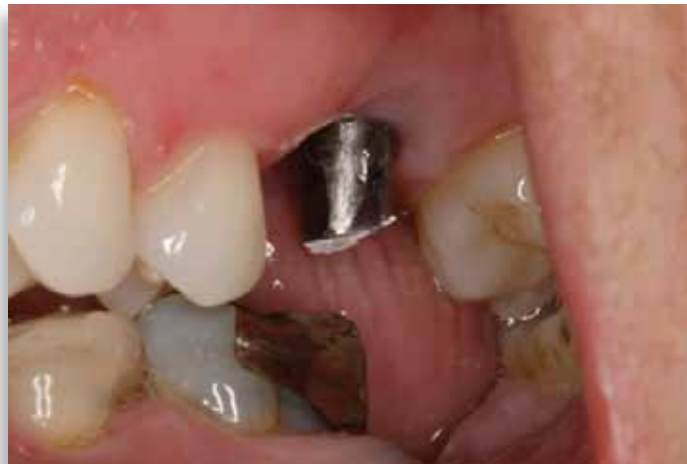

Figure 32: The abutment screw opening is covered with silicone or cotton and Cavit before crown cementation.

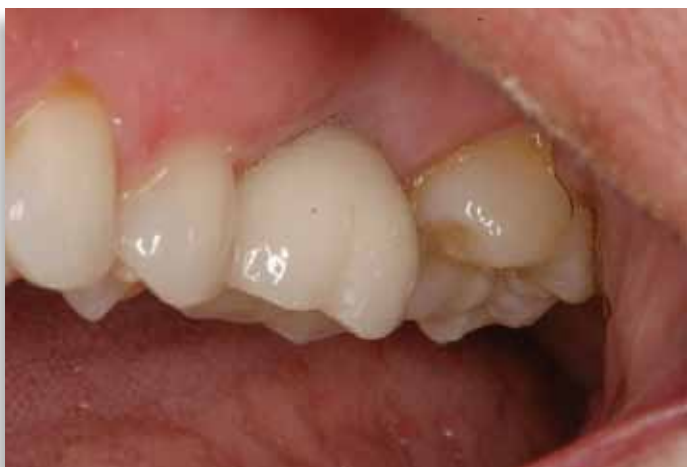

Figure 33: The PrismaTik CZ crown is cemented onto the abutment.

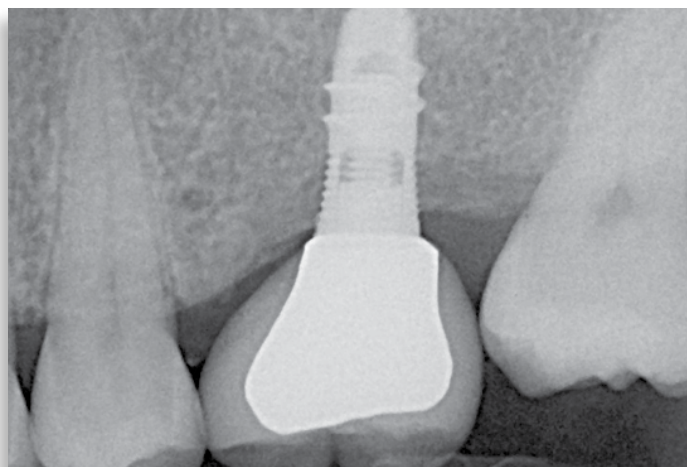


Figure 34: PA of the final restoration.